



2025

KARNATAKA RADIOLOGY EDUCATION PROGRAM

Chief complaints

Name: Mr. X

Age/Sex: 63-year-old Male

Chief Complaint

Right-sided nasal obstruction for 6 months

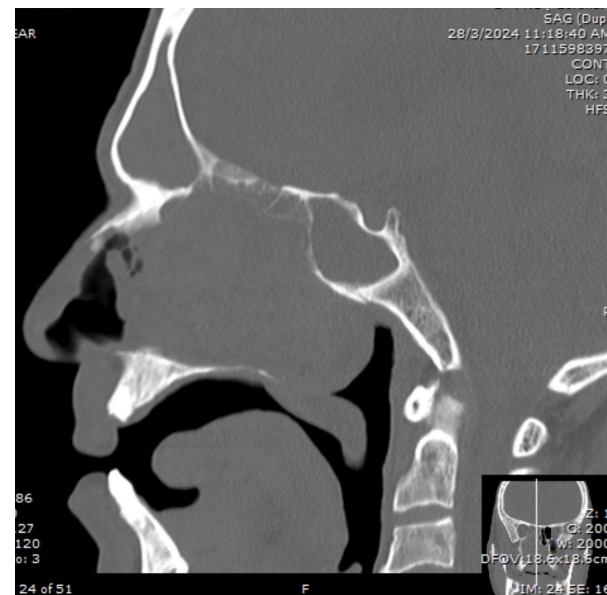
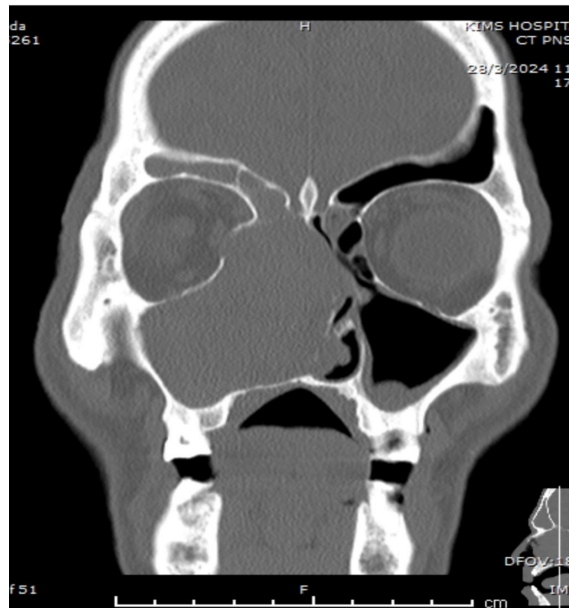
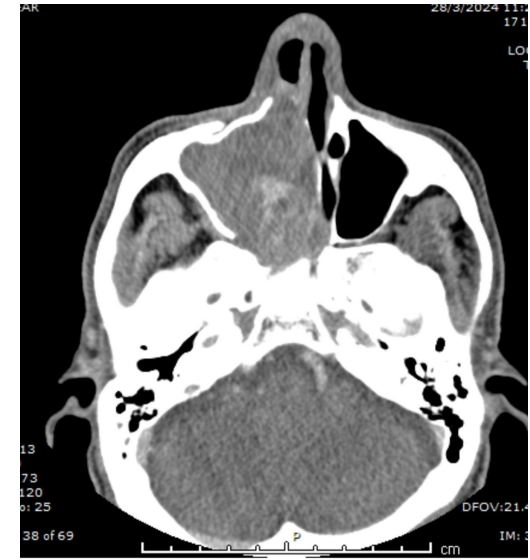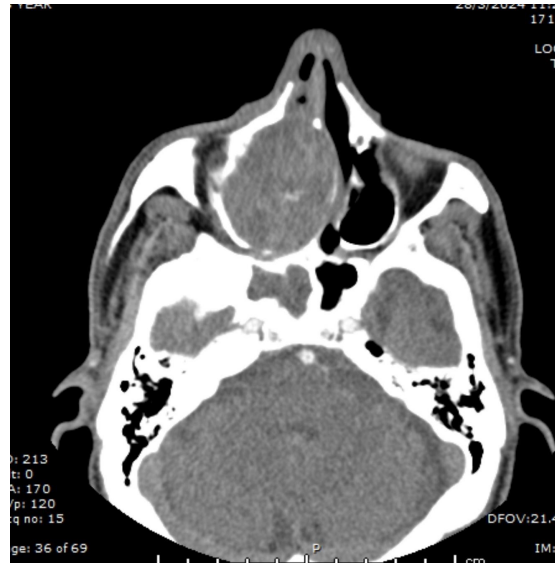
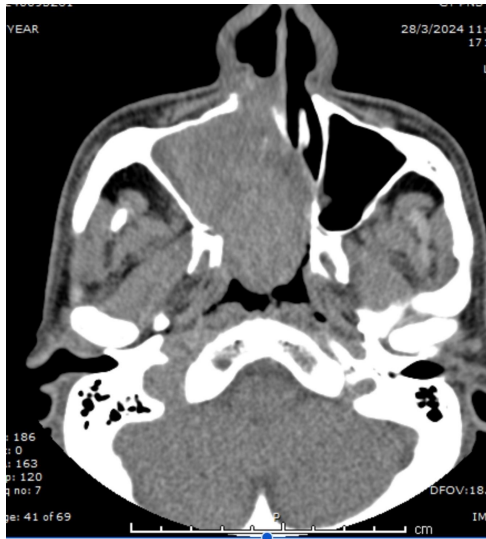
History of presenting illness:

Unilateral nasal obstruction on the right side, gradually worsening.

Intermittent epistaxis—mild, self-limiting episodes occurring 1–2 times a week.

Watery to mucoid nasal discharge, occasionally blood-tinged.

CT



CT FINDINGS

- Evidence of soft tissue density lesion measuring 5.3x4.7cm epicentered at right maxillary antrum extending along hiatus semilunaris into middle meatus extending superiorly to frontal sinus , inferiorly, to inferior meatus causing mass effect on inferior and medial walls of orbit, Laterally causing pressure erosion of superior middle turbinate causing compression of nasal septum showing cerebriform pattern of enhancement -->f/s/o inverted papilloma.
- Right frontal , anterior and posterior ethmoid sinusitis.
- **F/S/O INVERTED PAPILLOMA.**

Differential diagnosis to be considered:

1. Inverted papilloma
2. Sinonasal carcinoma

Impression: **LESION SHOWS CEREBRIFORM
ENHANCEMENT EPICENTERED AT RIGHT
MAXILLARY SINUS WITH EXTENSIONS AS
DESCRIBED –S/O INVERTED PAPILLOMA**

MENTORS

Dr.G.C.Patil

PROFESSOR
DEPT OF RADIO DIAGNOSIS
KMCRI HUBLI.

Dr.J.G.Sutagatti

HOD AND PROFESSOR
DEPT OF RADIO DIAGNOSIS
KMCRI HUBLI

All professors and teaching staff ,department of radiodiagnosis KMCRI HUBLI

THANK YOU